

AAD ANNUAL MEETING **2026**

AEDV

highlights
Denver, Colorado

27 — 31
Marzo

[A un nuevo nivel de conocimiento científico]

Una iniciativa de:



Con el patrocinio de:



AAD ANNUAL MEETING 2026

AEDV

highlights

Denver, Colorado

27 — 31
Marzo



**Dermatitis atópica e inmunoalergia
cutánea**

**Redefiniendo la fisiopatología hacia nuevos
mecanismos de acción**

Alberto Guerrero

Hospital Universitario Infanta Cristina

@dr.guerreroerma

highlights
Denver, Colorado

A A D A N N U A L M E E T I N G 2 0 2 6

27 — 31
Marzo

AEDV

*A un nuevo nivel de
conocimiento científico*



Video 2: Prurigo nodular y urticaria

Una iniciativa de:



Con el patrocinio de:



#AEDVenAAD2026

CONFLICTO DE INTERÉS


- He participado como ponente y/o consejero/asesor y/o recibido financiación en investigación de Almirall, Leo Pharma, Novartis, Sanofi–Regeneron, Abbvie, Galderma y Pfizer
- Recibo honorarios por esta presentación

AEDV

highlights

27 — 31

November 27-31, 2026



Indice

Video 1

- Dermatitis atópica

Video 2

- Prurigo nodular
 - Formas clínicas
 - Pruebas complementarias
 - Tratamiento
- Urticaria
 - Redefiniendo fisiopatología en UCE
 - Actualización guías clínicas
 - Tratamiento en UCE y urticarias inducibles

highlights
Denver, Colorado

A A D A N N U A L M E E T I N G 2 0 2 6

27 — 31
Marzo

AEDV

*A un nuevo nivel de
conocimiento científico*



Prurigo nodular

Una iniciativa de:



Con el patrocinio de:

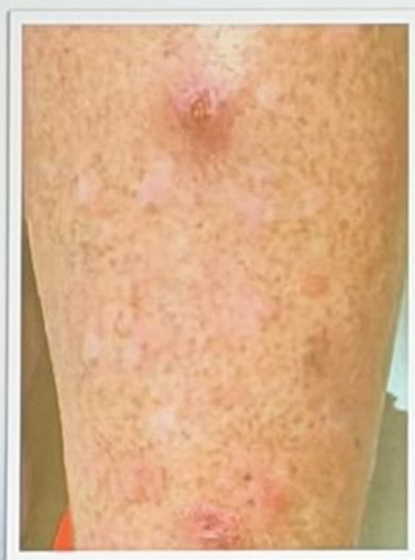

#AEDVenAAD2026

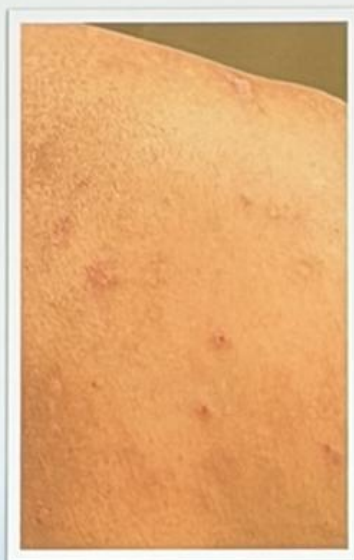Prurigo nodular

Multiple Morphologies of Prurigo Lesions

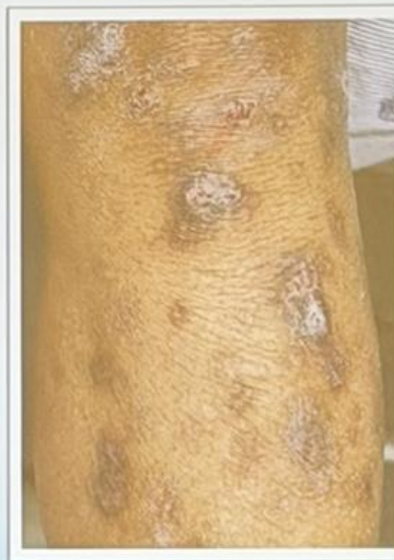Nodules are the most common skin lesion, but patients may present with multiple other morphologic subtypes



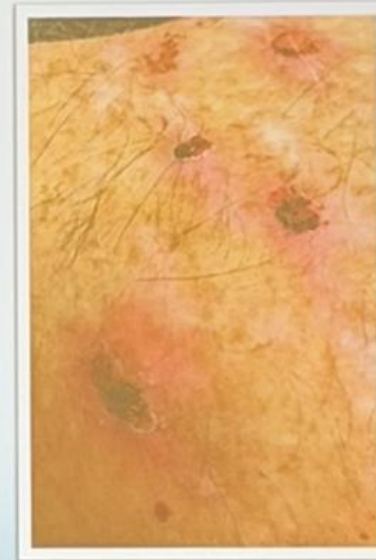
Nodular



Papular

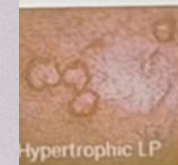
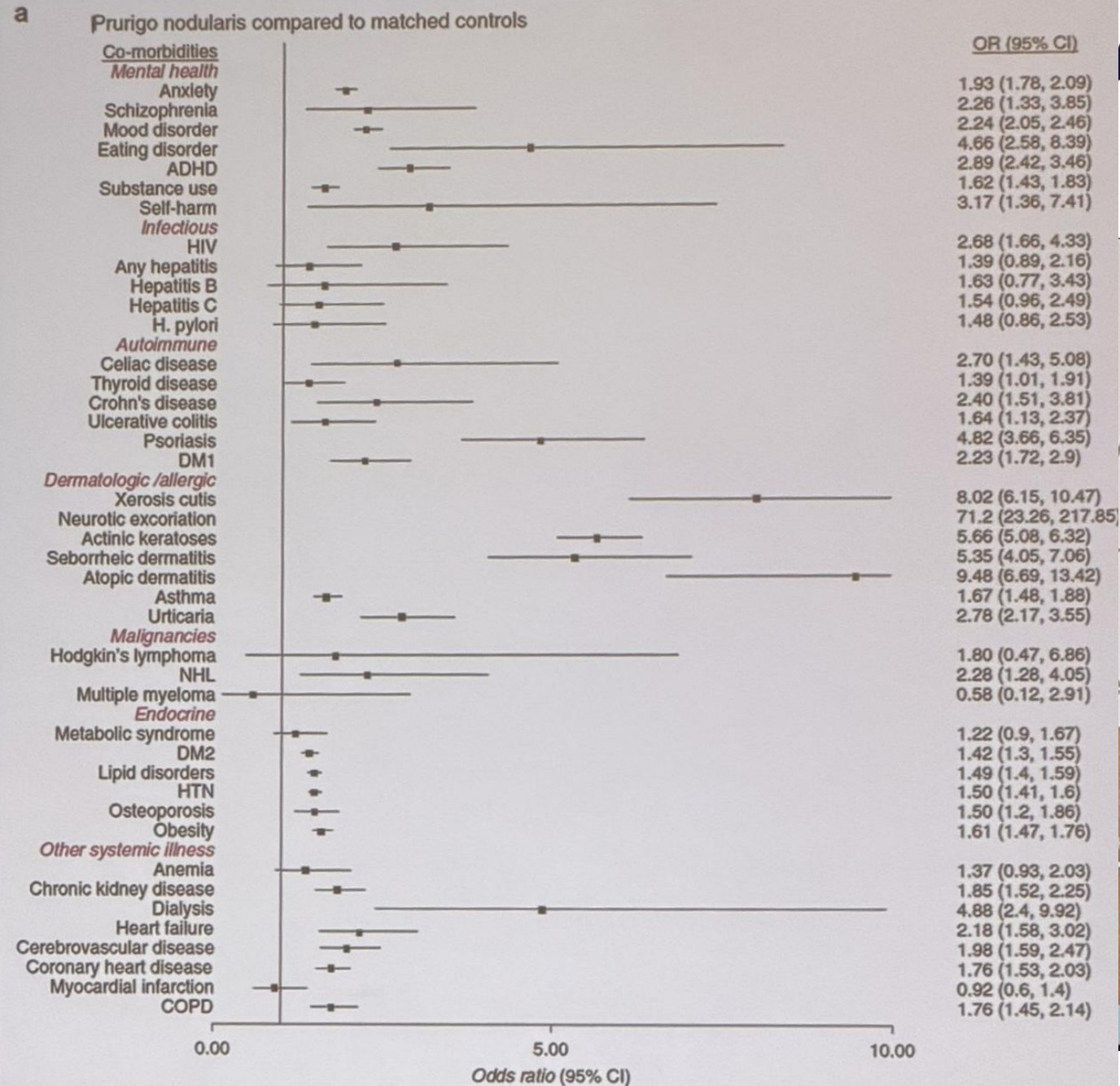


Plaque



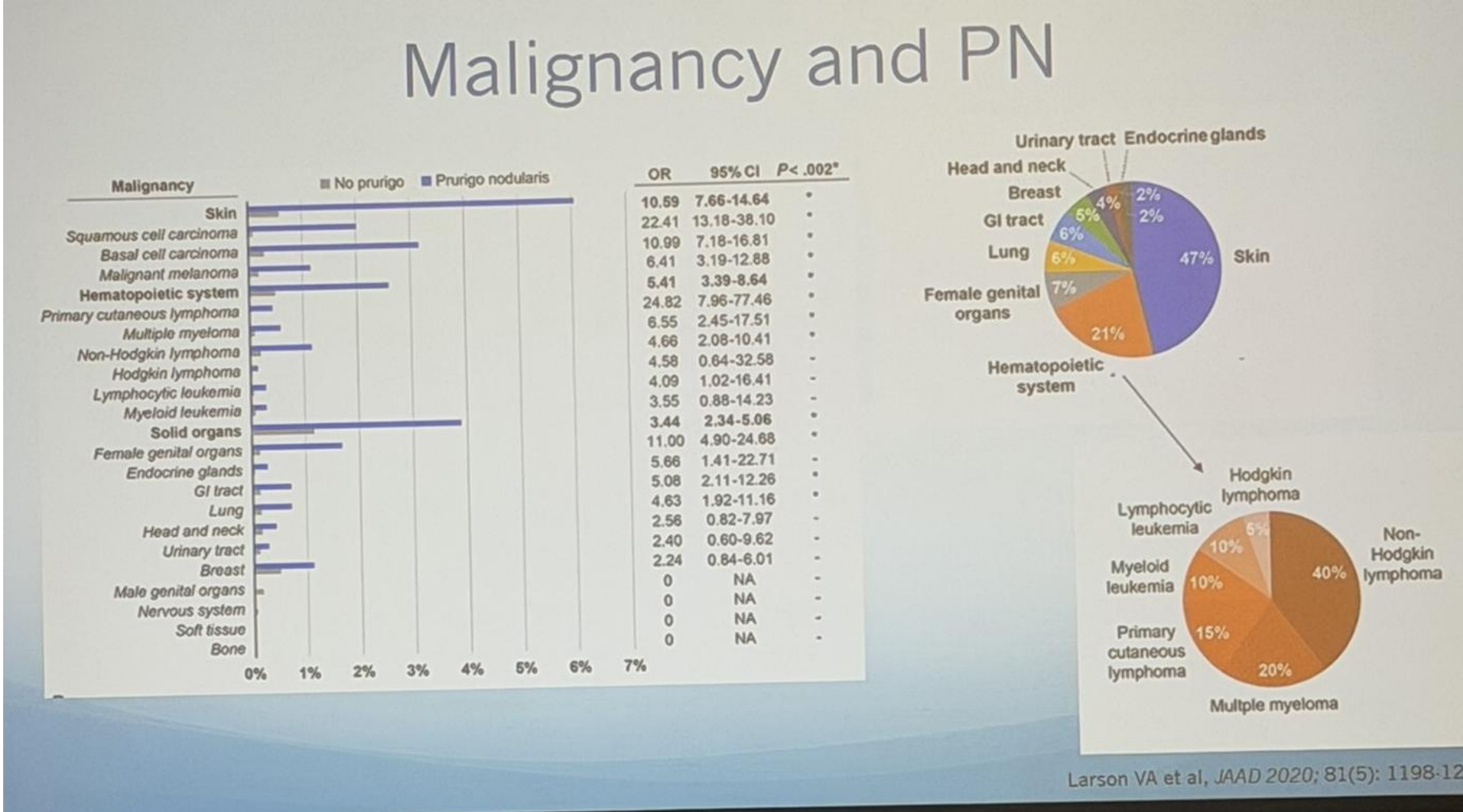
Ulcerated

Prurigo nodularis



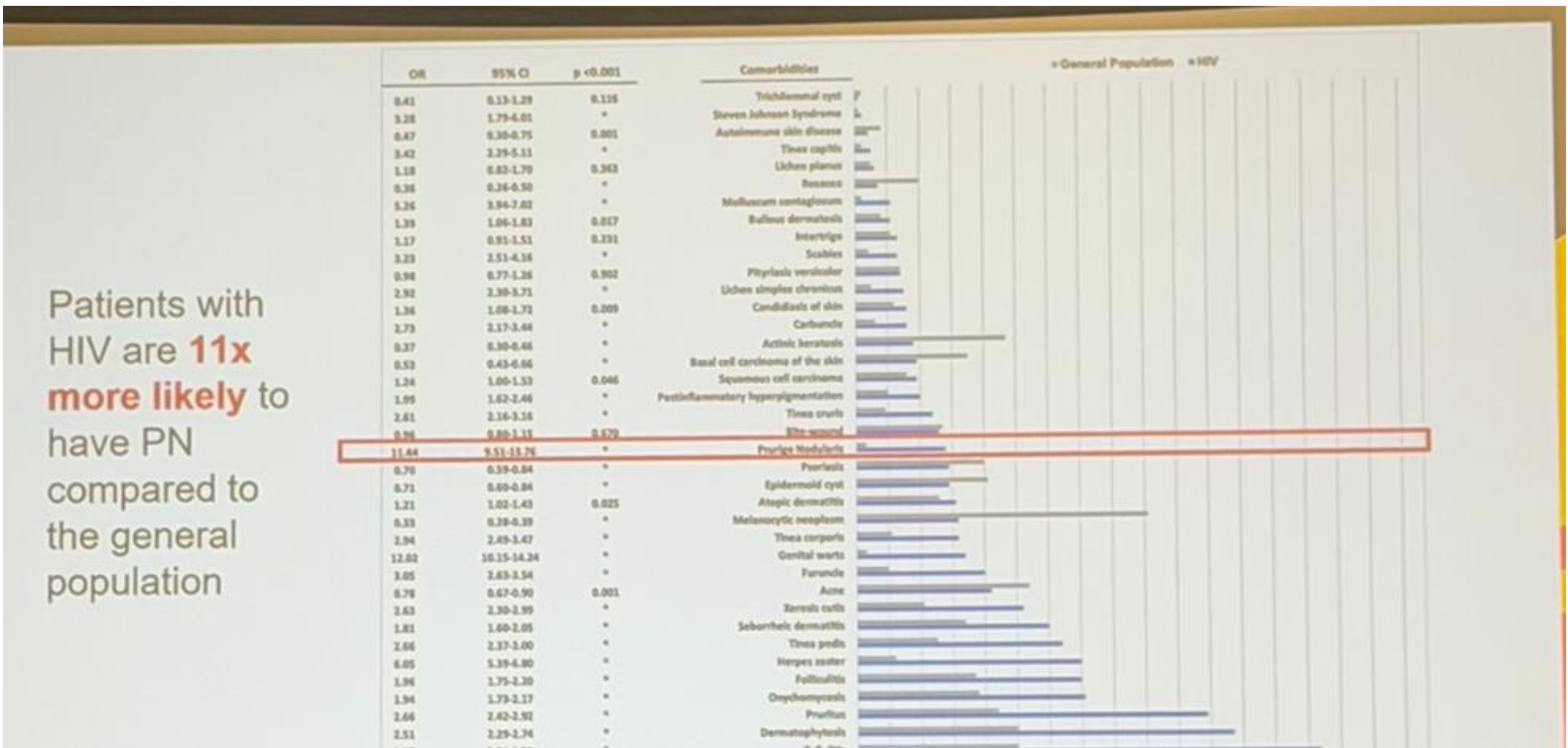
Diseaseshows.com,

Prurigo nodular



Larson VA et al, JAAD 2020; 81(5): 1198-1200

Prurigo nodular

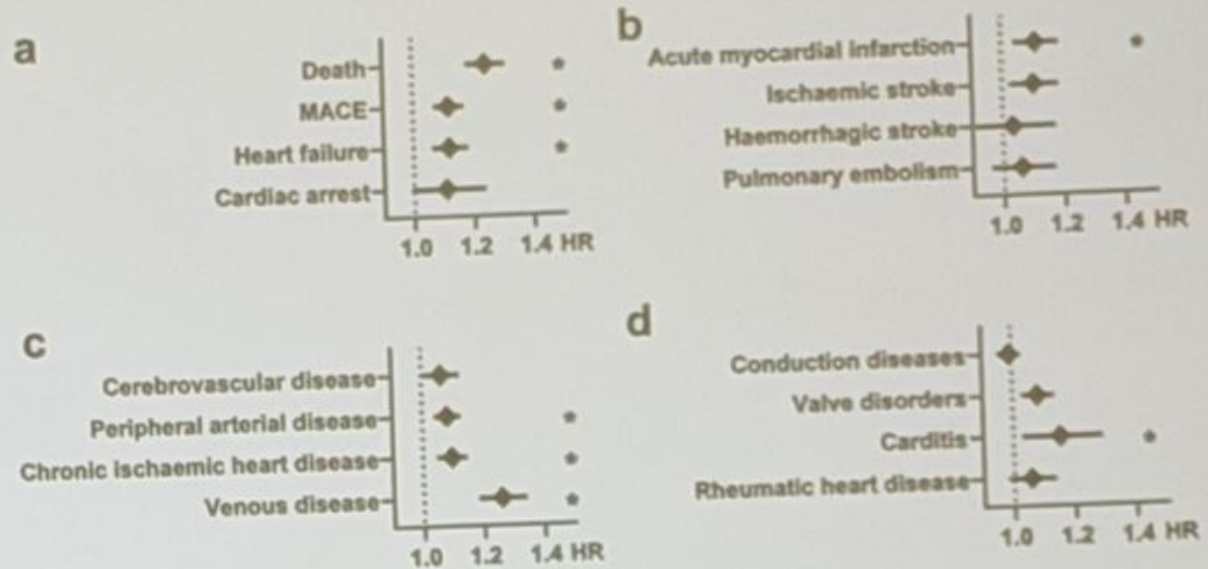


Patients with HIV are **11x more likely** to have PN compared to the general population

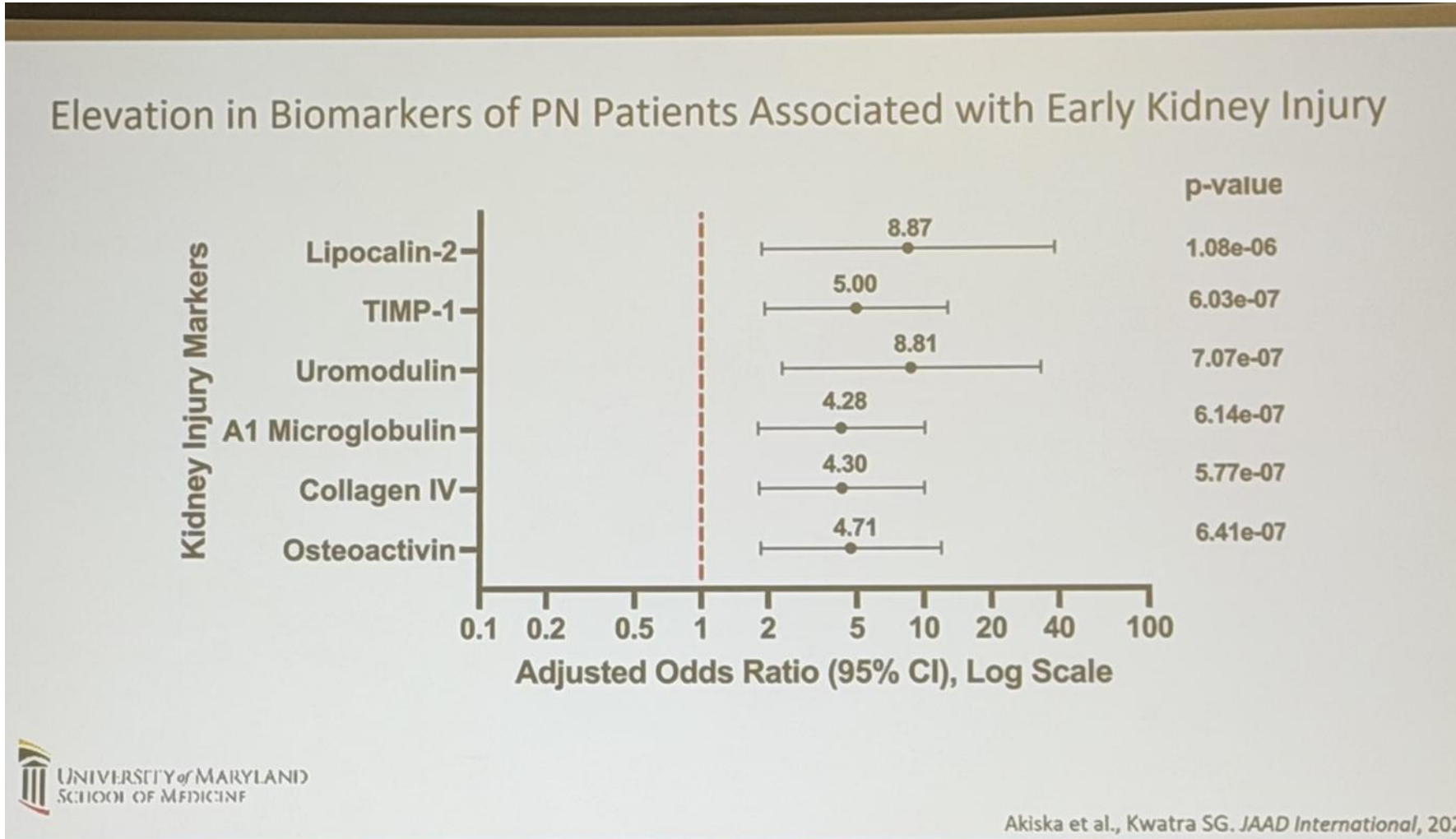
Prurigo nodular

Cardiovascular Risk in PN

- PN patients have increased risk of **major adverse cardiovascular events (MACE)**, including:
 - Heart failure
 - Heart attack
 - Cardiac arrest
 - Stroke



Prurigo nodular



Tratamientos

- Corticoides tópicos

Case Reports > J Dermatol Treat. 2016 Oct;27(5):425-6.
doi: 10.3109/09546634.2015.1136049. Epub 2016 Jan 29.

Localized topical steroid use and central serous retinopathy

Lauren Y Chan ¹, Robert S Adam ², David N Adam ³

Affiliations + expand
PMID: 26822912 DOI: 10.3109/09546634.2015.1136049

CASE REPORT - Volume 6, Issue 6, Pages 495-501, September 2020 - Open Access [Download Full Issue](#)

Topical dermal steroid-induced retinopathy

Taylor Milton, MS ^a · Andrew DeCrescenzo, MD ^b · Alan Mentzer, MD ^b · Sai H. Chavala, MD ^{a,c,d}

Affiliations & Notes Article Info

<http://handlinline.com/jdt>
ISSN: 0954-6634 (print), 1473-1733 (electronic)
J Dermatol Treat, 2016, 27(5): 425-426
© 2016 Informa UK Limited, trading as Taylor & Francis Group. DOI: 10.3109/09546634.2015.1136049

Journal of Dermatological Treatment
Taylor & Francis

CASE REPORT

Localized topical steroid use and central serous retinopathy

Lauren Y. Chan¹, Robert S. Adam², and David N. Adam³

¹School of Medicine, Queen's University, Kingston, ON, Canada, ²Division of Ophthalmology, Department of Surgery, University of Toronto, Toronto, ON, Canada, and ³Division of Dermatology, Department of Medicine, St. Michael's Hospital, University of Toronto, Toronto, ON, Canada

UNIVERSITY OF MARYLAND
SCHOOL OF MEDICINE

LETTER TO THE EDITOR

Topical steroid induced central serous chorioretinopathy- a rare side-effect

Choudhary, Paras; Gole, Prachi Vinayak; Darkase, Bhushan Amol; Malikar, Balasaheb Vishwas

Author Information

Indian Journal of Drugs in Dermatology 8(1):p 49-51, Jan-Jun 2022. | DOI: 10.4103/ijdd.ijdd_40_20

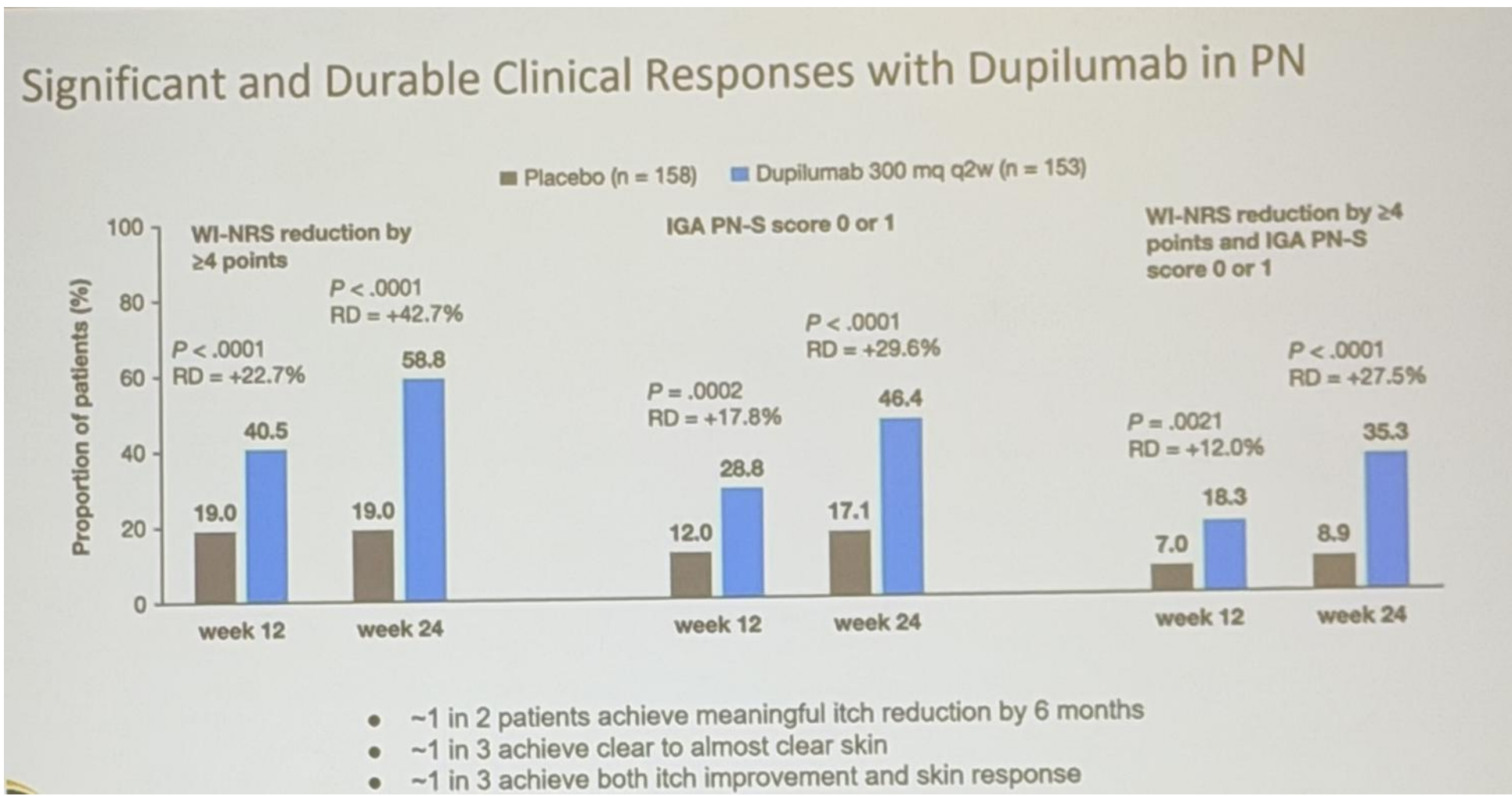
LETTER TO THE EDITOR [Full Access](#)

Topical steroid-induced visual disturbances related to central serous chorioretinopathy. A potentially serious complication of dermocorticoids

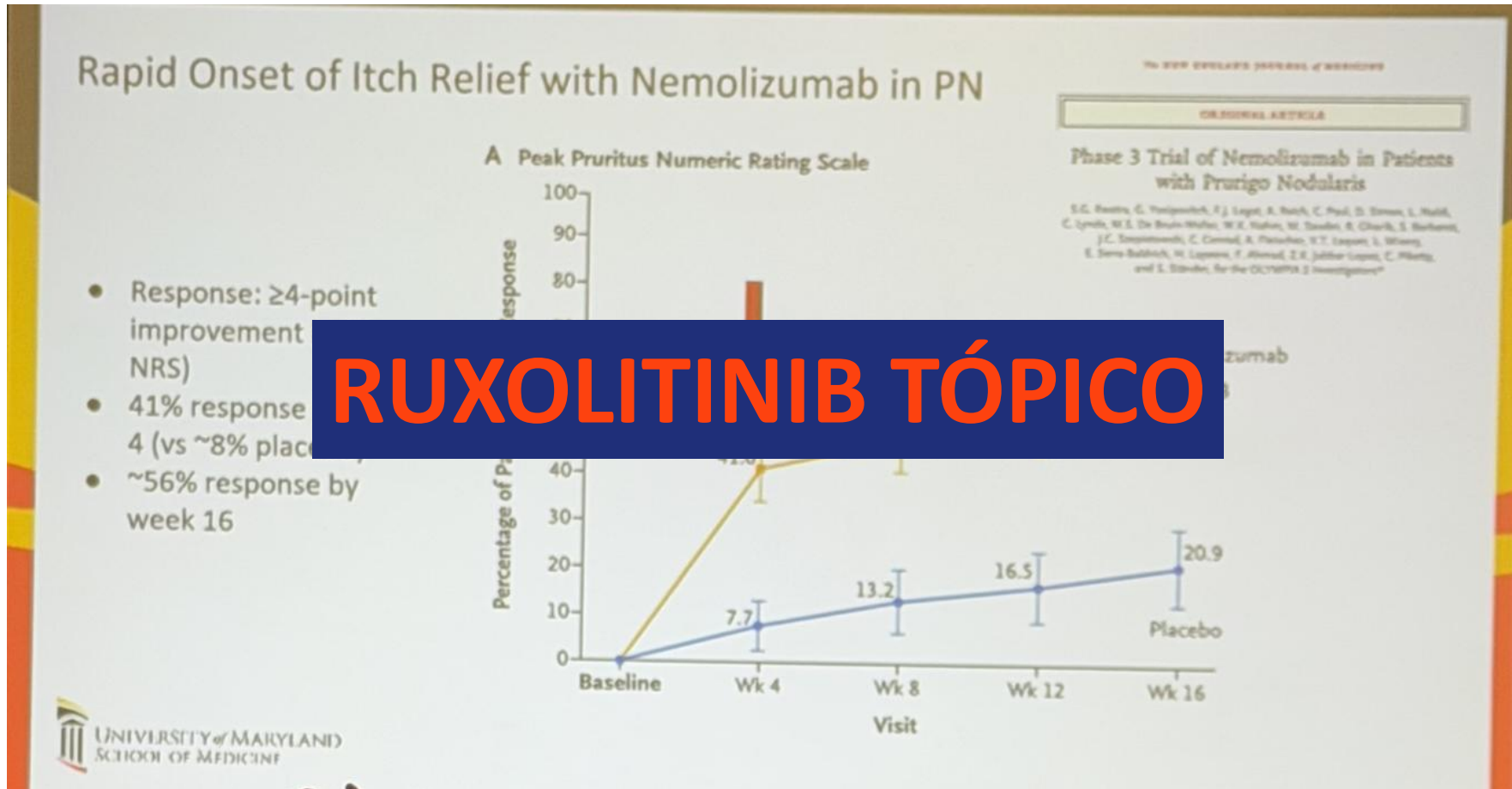
Gabriel Linsker Matthew Wurst, Dan Linsker

First published: 15 November 2022 | <https://doi.org/10.1111/jid.18729> [VIEW METRICS](#)

Tratamiento



Tratamiento



highlights
Denver, Colorado

A A D A N N U A L M E E T I N G 2 0 2 6

27 — 31
Marzo

AEDV

*A un nuevo nivel de
conocimiento científico*

Urticaria

Una iniciativa de:



Con el patrocinio de:

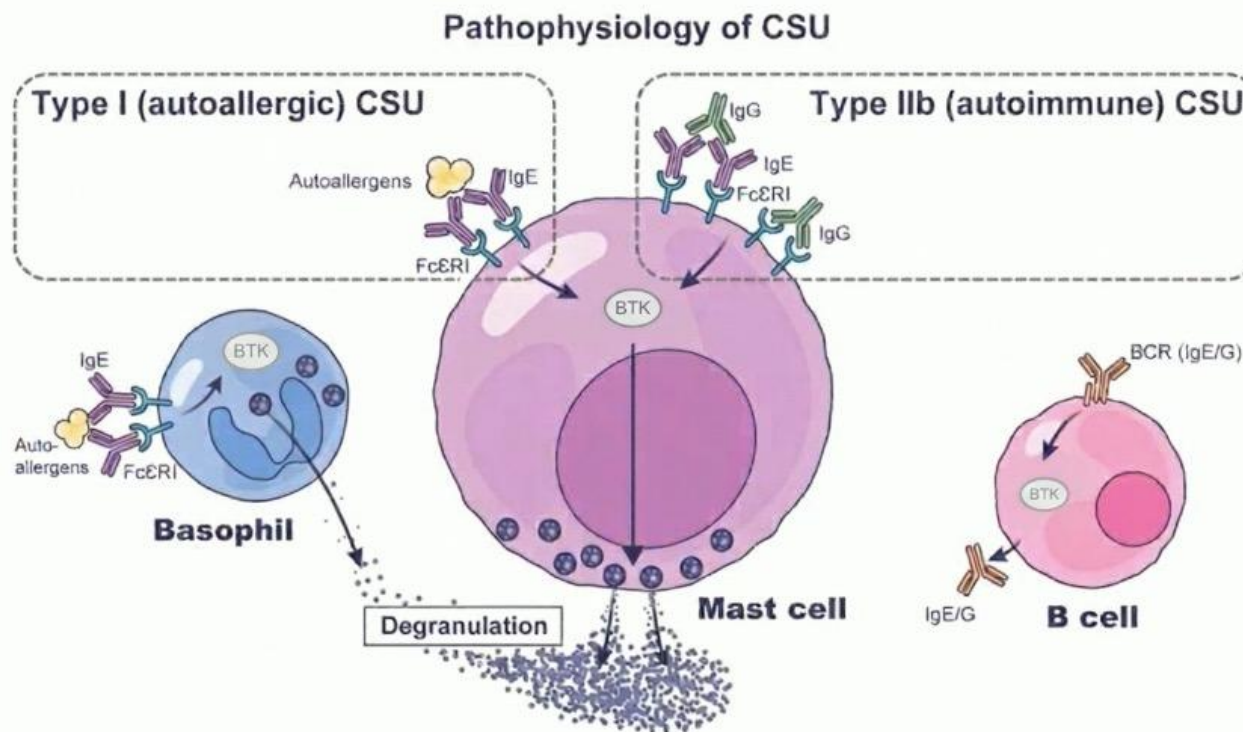
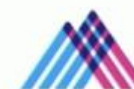

#AEDVenAAD2026

Fisiopatología



What is the pathophysiology of CSU?

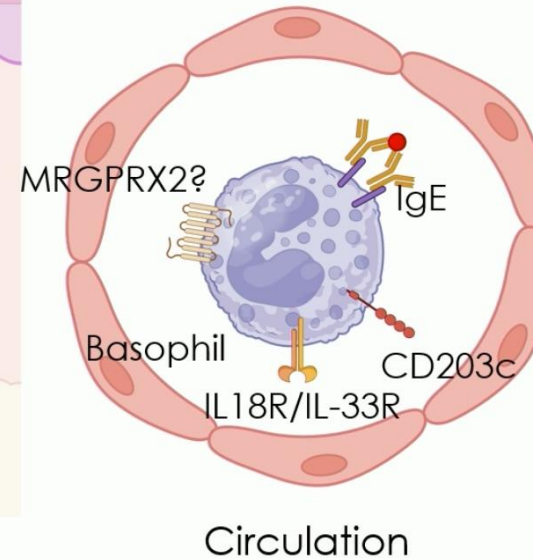
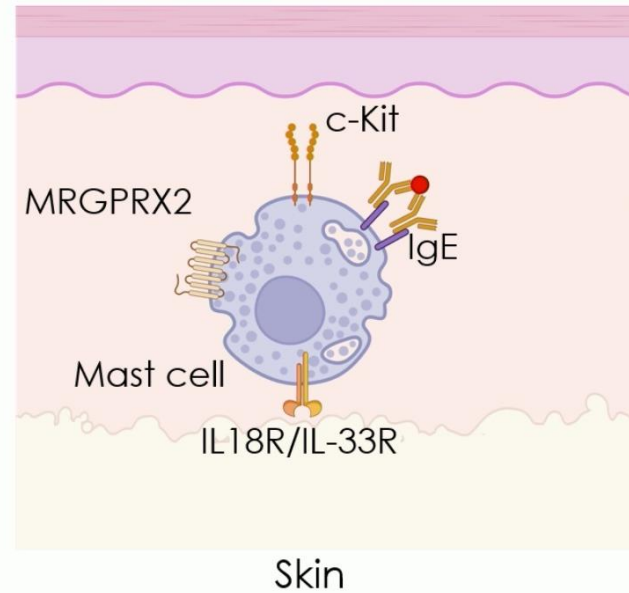


Metz et al. NEJM 2025

Fisiopatología

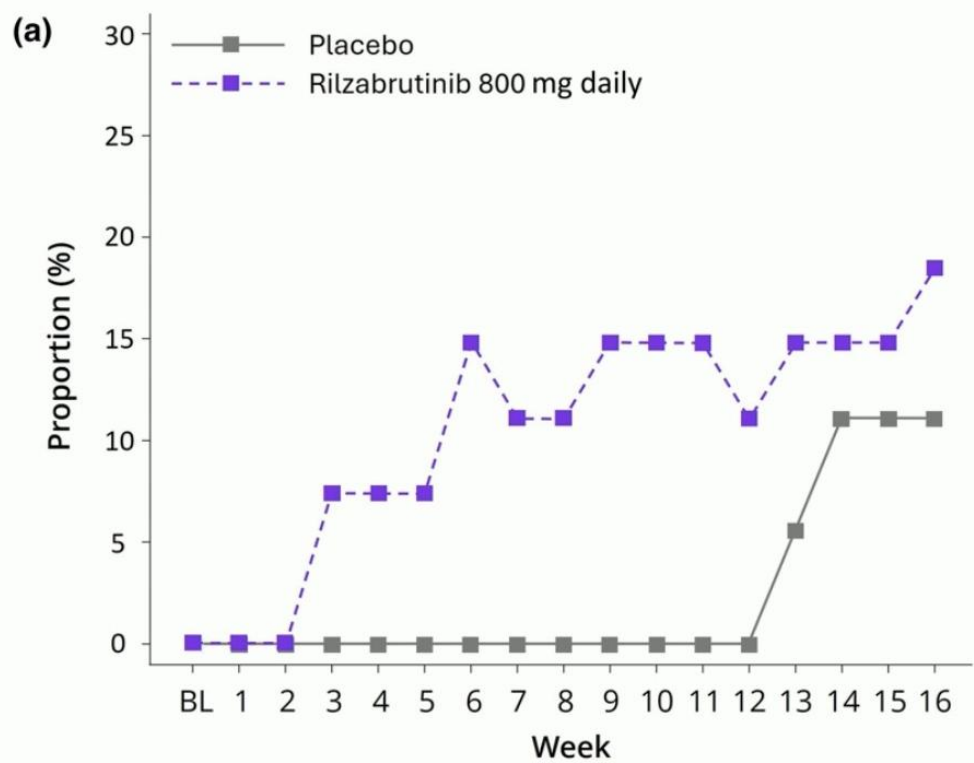


Mast cells and basophils represent unique targets in CSU and beyond



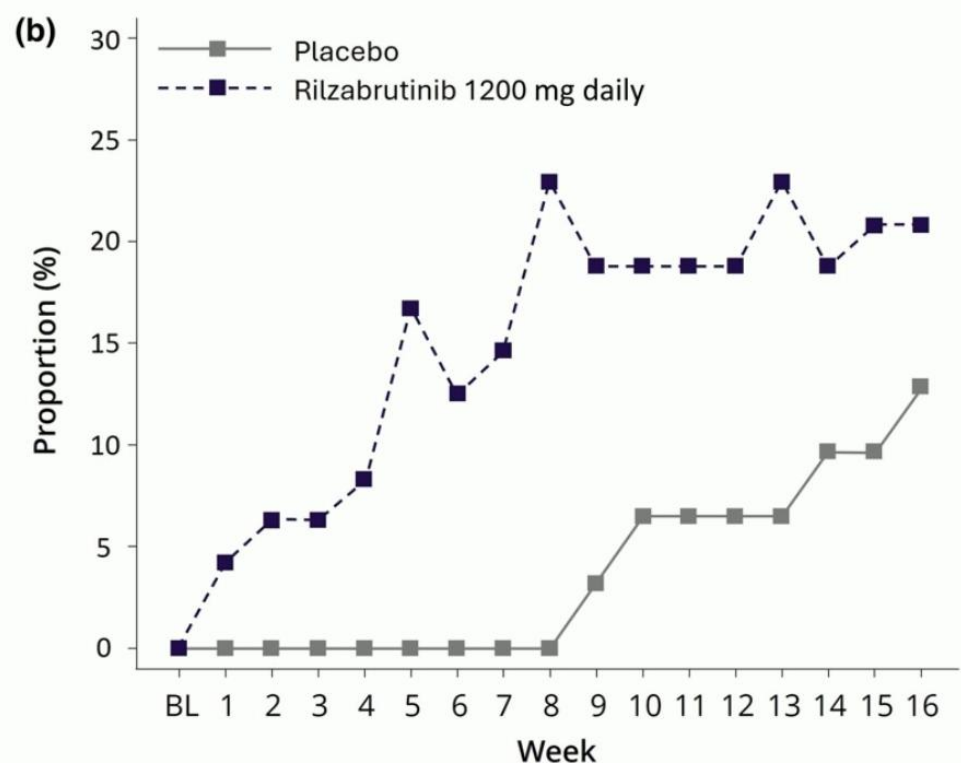


BTK inhibitors in AD



#Participants

	BL	1	2	3	4	5	6	7	8	9	10	11	12	13	14	15	16
Placebo	18	18	18	18	18	18	18	18	18	18	18	18	18	18	18	18	18
Rilzabrutinib 800 mg daily	27	27	27	27	27	27	27	27	27	27	27	27	27	27	27	27	27



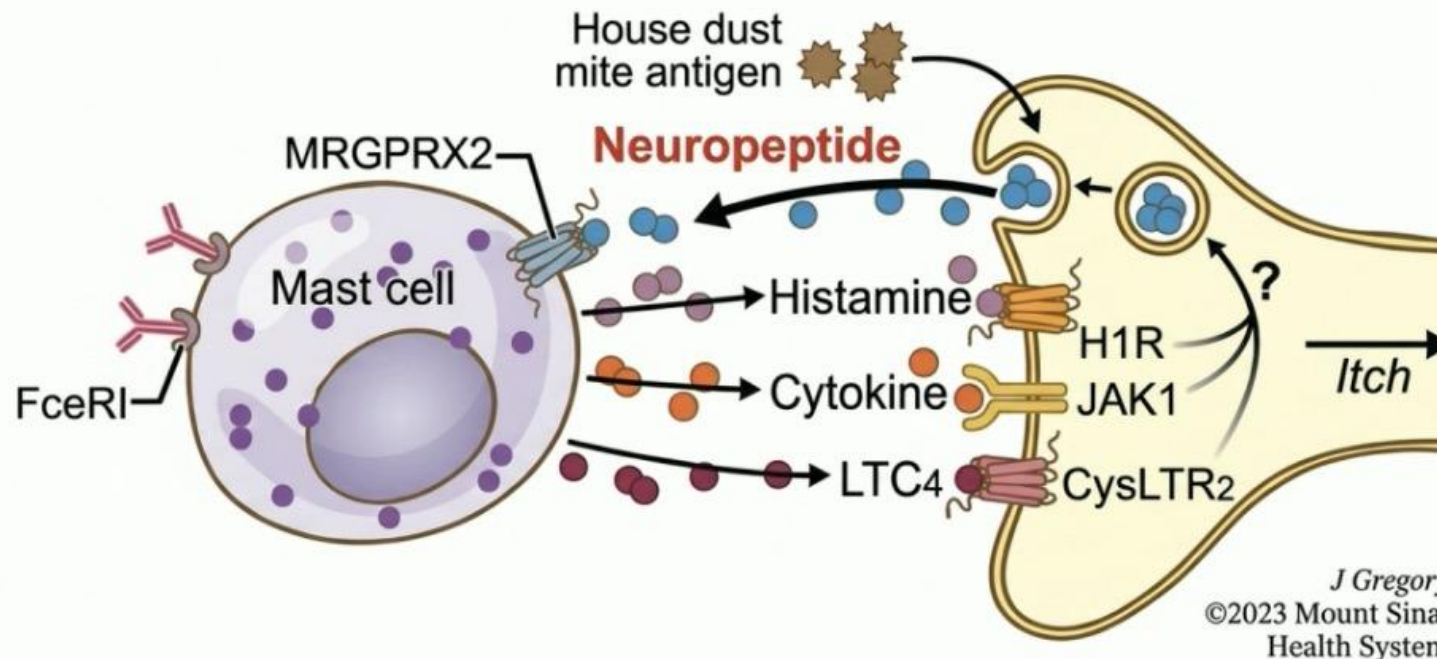
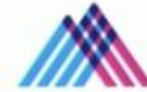#Participants

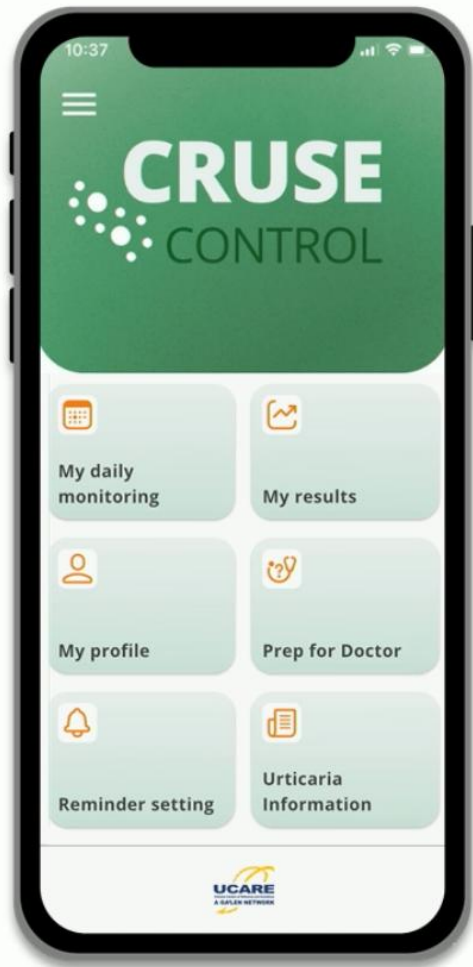	BL	1	2	3	4	5	6	7	8	9	10	11	12	13	14	15	16
Placebo	31	31	31	31	31	31	31	31	31	31	31	31	31	31	31	31	31
Rilzabrutinib 1200 mg daily	48	48	48	48	48	48	48	48	48	48	48	48	48	48	48	48	48

Fisiopatología



What about chronic inducible urticaria (CIndU)?





- ChRonic
- Urticaria
- Self-
- Evaluation



Sophia Neisinger

 sophia.neisinger@charite.de



PROVIDED BY



SUPPORTED BY

Platinum sponsor:



Supporters:



Trata

Efficacy of dupilumab in CSU

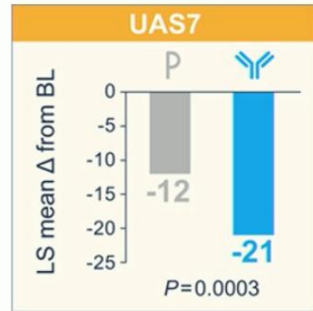
Results of the CUPID A & B trials

CUPID Study A

138 patients

Aged ≥ 6 years

Omalizumab-naïve

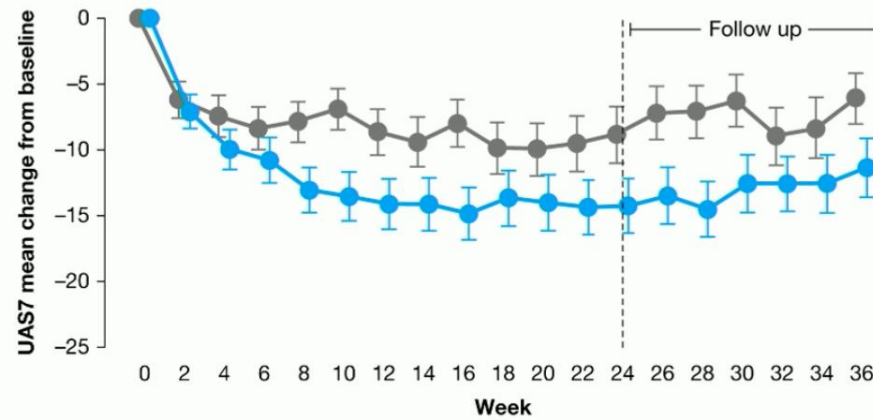
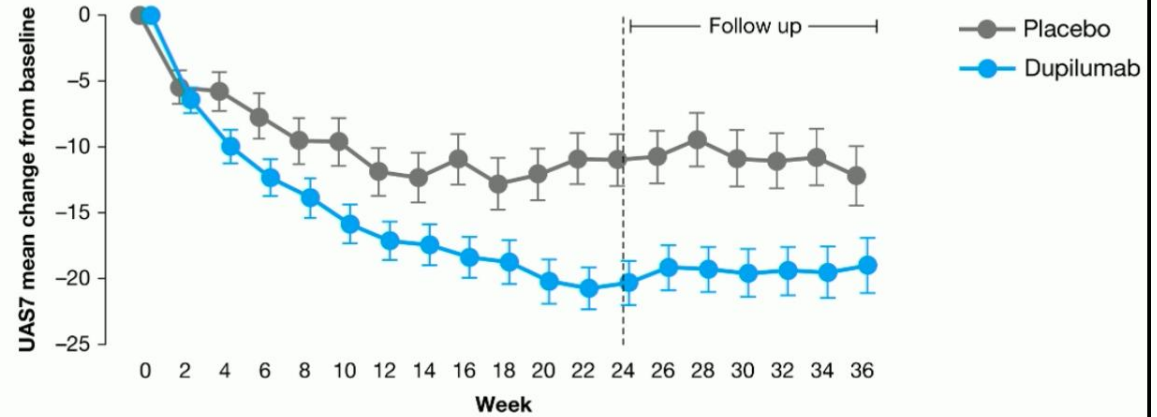
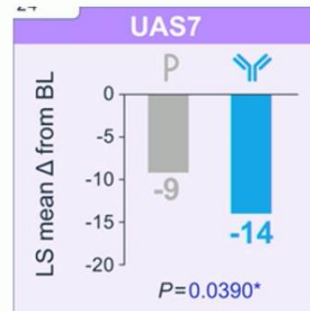


CUPID Study B

108 patients

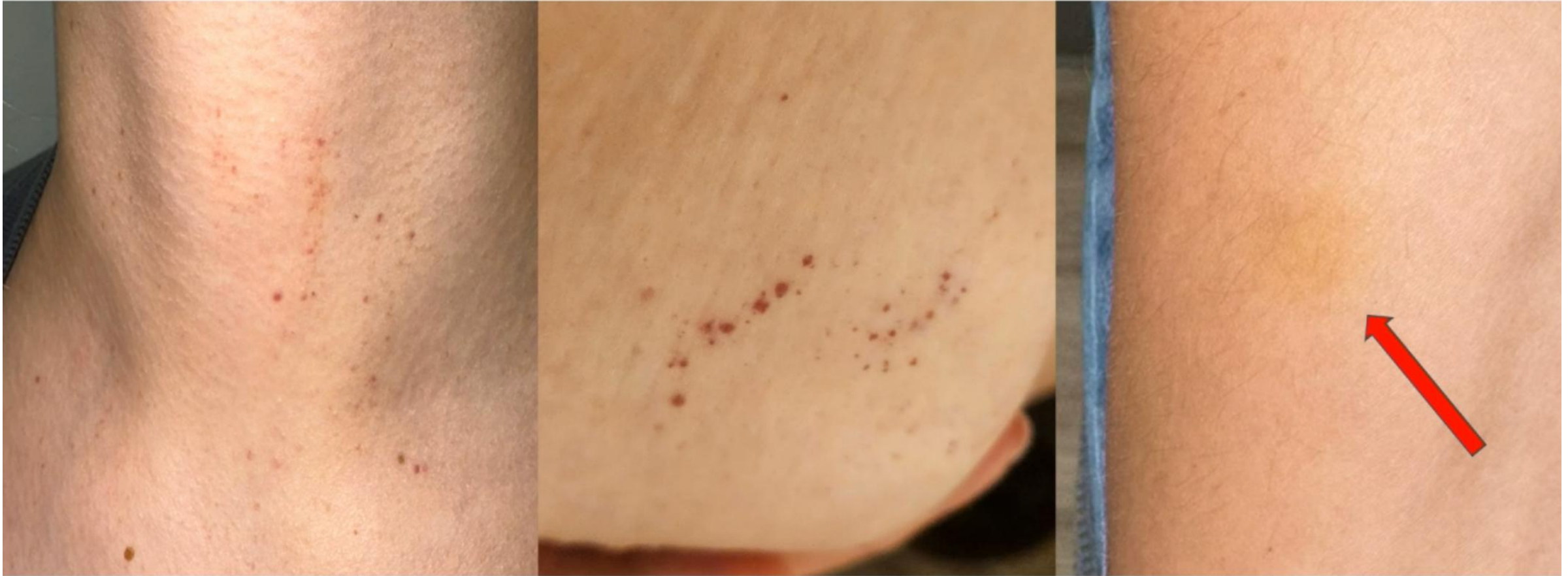Aged ≥ 12 years

Omalizumab-intolerant/
incomplete responders



Maurer et al., J Allergy Clin Immunol 2024; 2024;154:184-194

TIP: Real-World Remibrutinib “Bleeding” Events

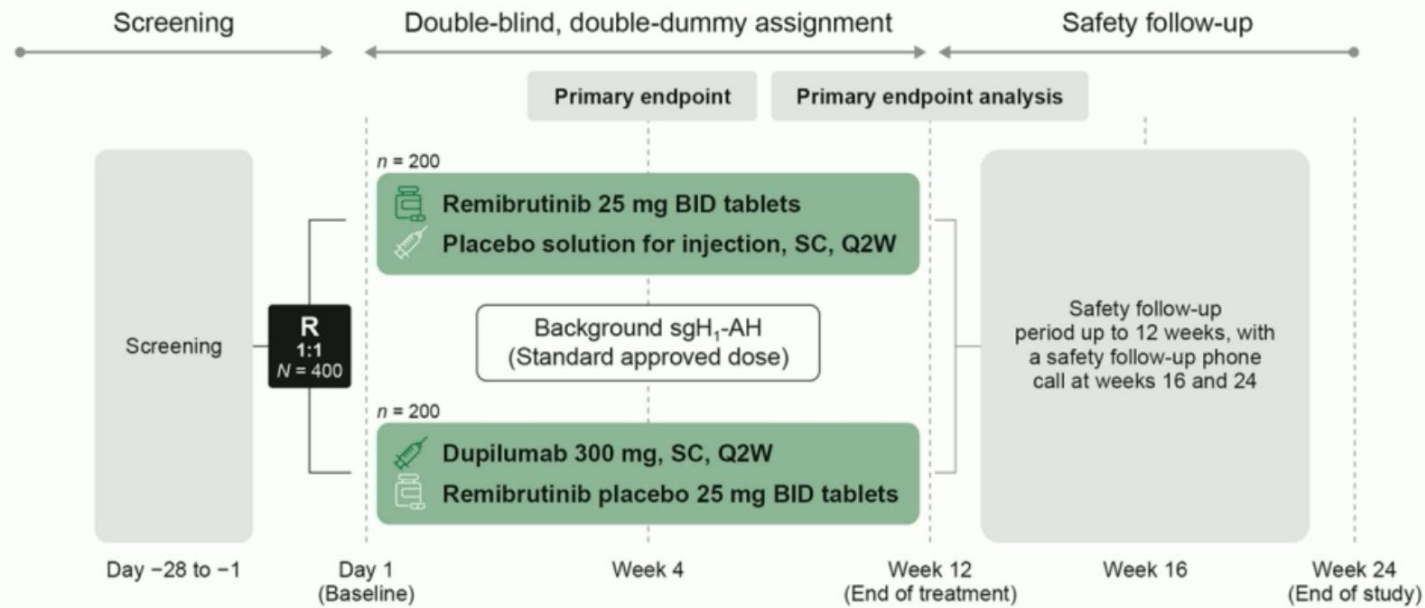


Chronic Inducible Urticarias Treatment with Phototherapy

CIndU Subtype	Clinical trials, randomized , double blind	Serie of cases or no controlled studies estudies with >5patients	Isolated cases or short series of patients
Sumptomatic dermatographism	Acrivastine, terfenadine, ebastine, cetirizine, ketotifen, omalizumab, nifedipine	Anti H1 +Anti H2, phototherapie , ciclosporine, ciclofosamide	IVIg, benralizumab (anti-IL5)
Cold Urticaria	Rupatadine, bilastine, desloratadine, ebastine, mizolastine, acrivastine, ciproheptadine, ketotifen, omalizumab, doxepine	Cinarizine, desensitization, doxicicline	Ciclosporine, danazol, etanercept, rituximab cetirizine /zafirlukast, anakinra, reslizumab (anti-IL5), dupilumab
Heat Urticaria	Ninguno	None	AntiH1, antiH1 + antiH2, omalizumab
Delayed Pressure	Desloratadine/montelukast, oxatomida/clemastine, colchicina	Omalizumab, sulfasalazine, teofiline, dapsone Oral and topic corticosteroids	Cumarina, cloroquine, anti-TNF α , Tranexámic acid, anakinra
Solar Urticaria	Cetirizine vs terfenadine omalizumab	antiH1/fsunscreen, antiH1/antileucotrienes, phototherapie , IVIG, α -melanotide	Cimetidine, ciclosporine, plasmaféresis, dupilumab, ligelizumab
Vibratory angioedema	None	None	Ketotifen, amitriptiline/bromazepam, omalizumab
Cholinergic urticaria	Cetirizine, acrivastine, ketotifen, antiH1 + antiH2, danazol, omalizumab	Desenaitization	Toxin botulínic ,surgery, ,scopolamine, beta-blockers, dupilumab
Aquagenic urticaria	None	None	PUVA /astemizol, antiH1 , Barrier cream, beta blockers, anticholinergics , omalizumab, fototherapie, stanozolol

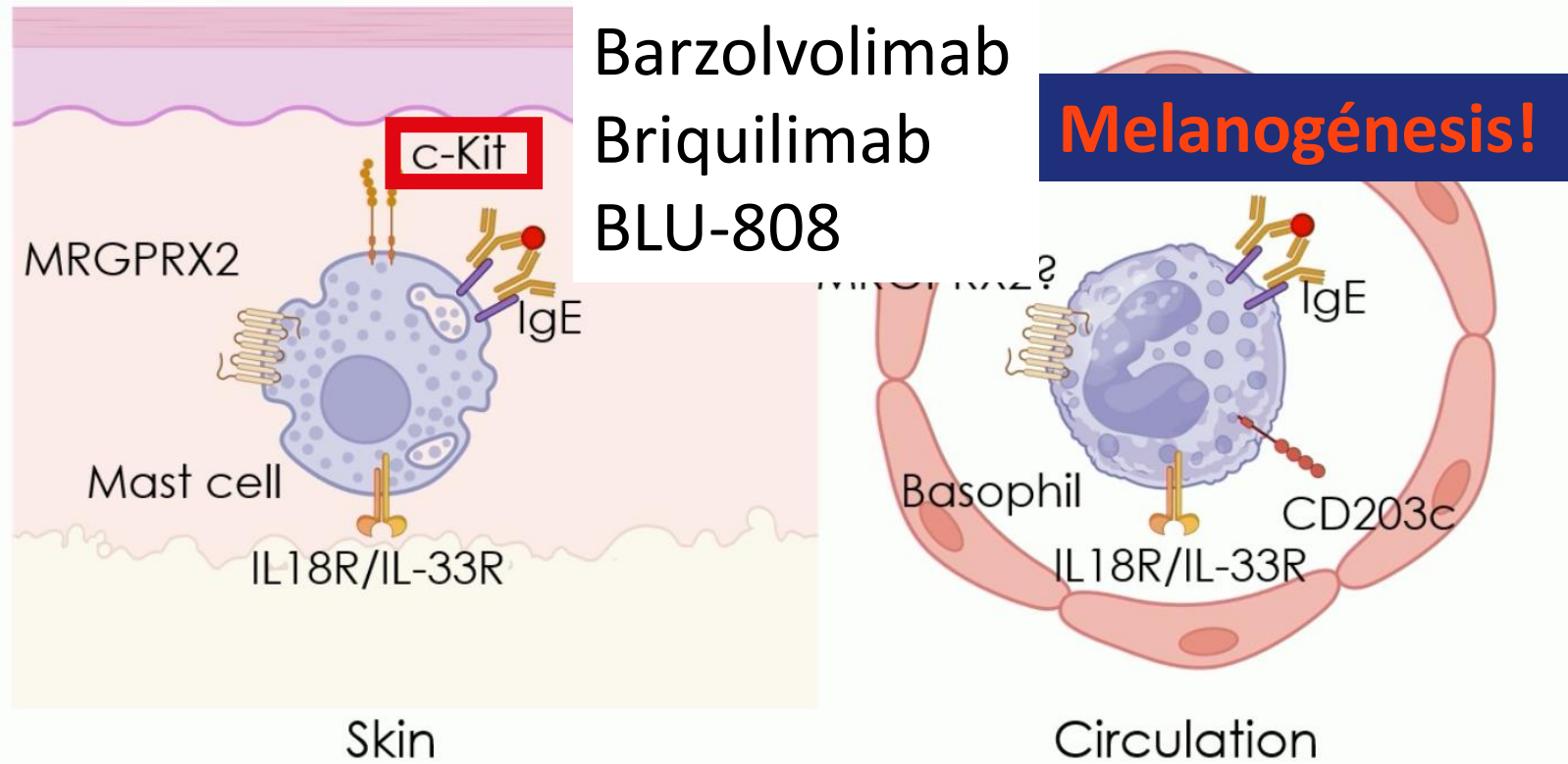
Futuro

RECLAIM (CSU, Ph 3b): Remibrutinib vs. Dupilumab



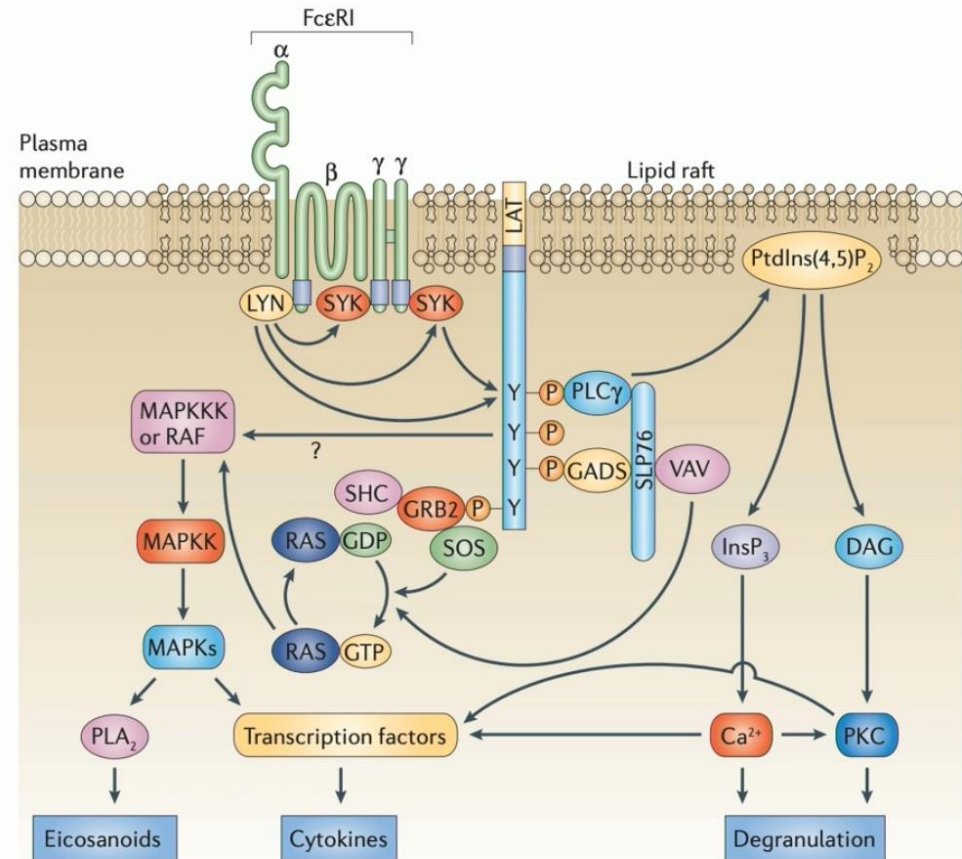
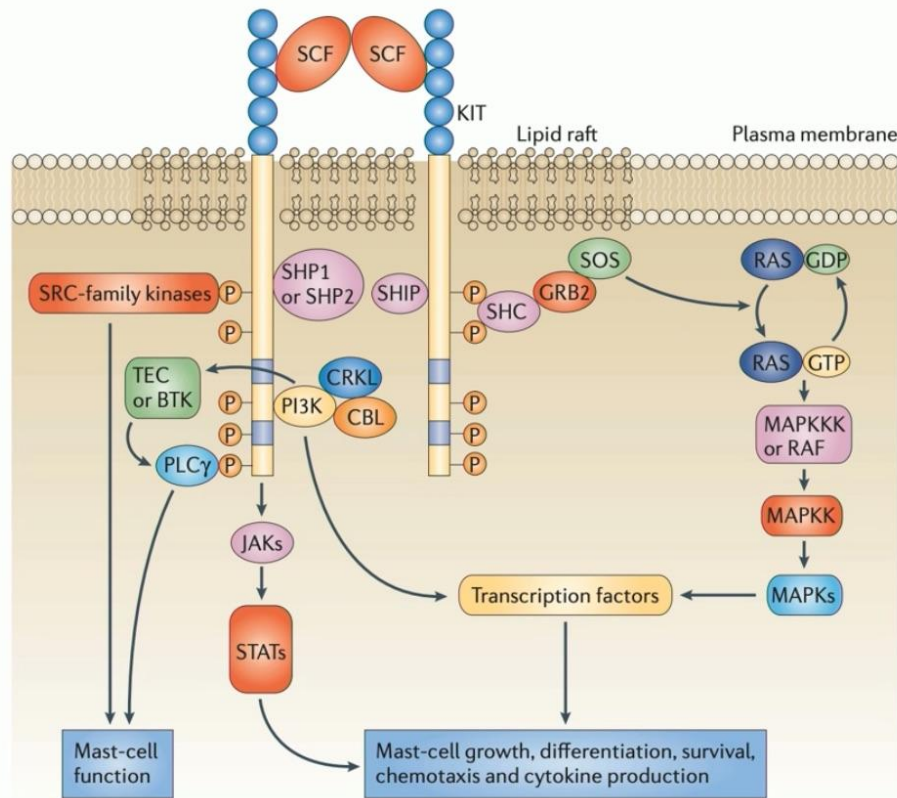


Mast cells and basophils represent unique targets in CSU and beyond

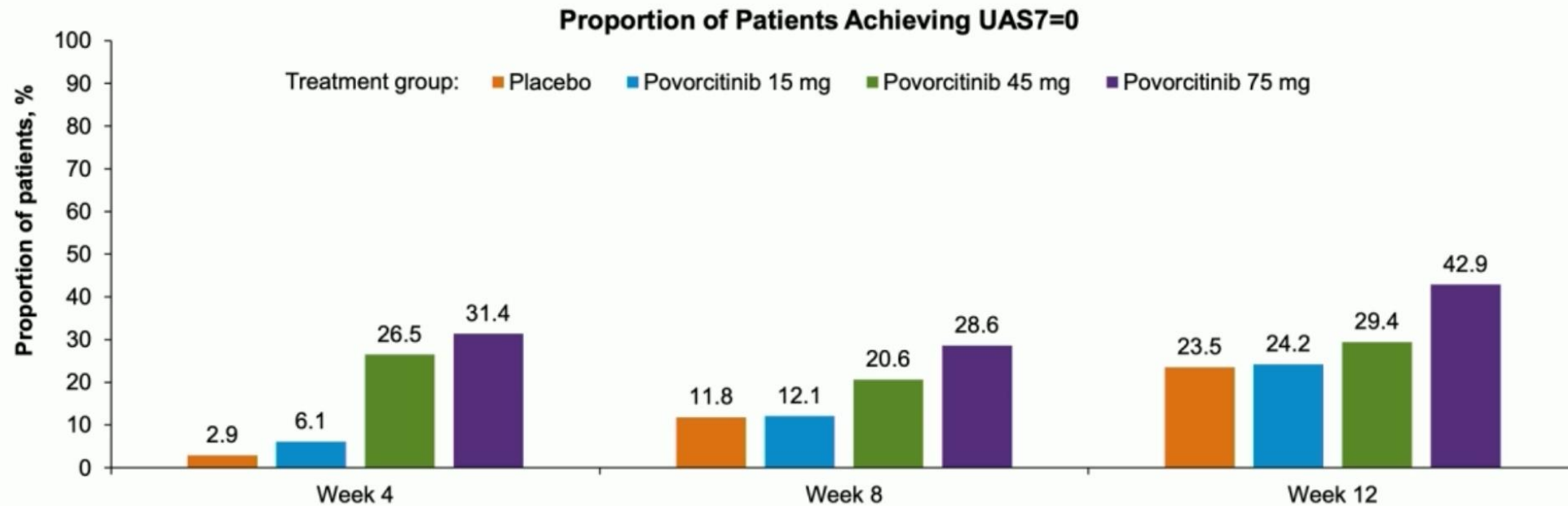


Futuro

JAK-STAT Signaling in Urticaria? A STAT5 Link



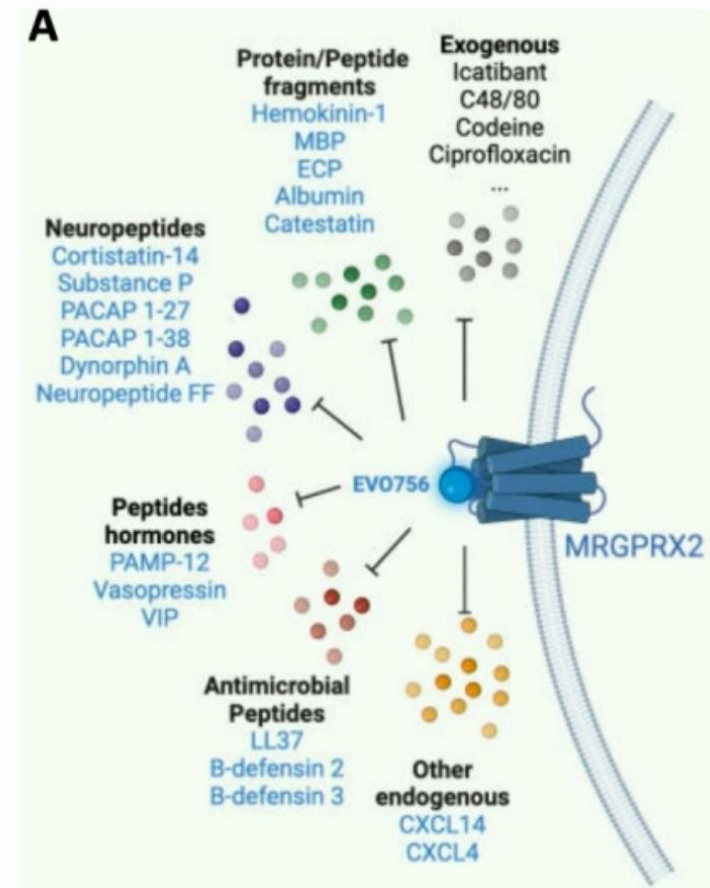
Povorocitinib: Oral, Selective JAK1 Inhibitor



- Phase 2 results promising: rapid onset of action, strong efficacy at highest dose (75 mg Qday)
- Rapid improvement in itch as early as day 3 (ie. JAK1 expressed on itch-sensory neurons)
- Safety: JAKi safety signal for highest dose – **Acne (20%)**; Question remains re black box warning if approved

Mas-related G-protein coupled receptor X2 (MRGPRX2)

- Expressed on MC and peripheral sensory neurons
- **Sentinel receptor:** activated by numerous environmental and endogenous peptides
- Critical innate immune response (rapid initial response)
- **EVO756** = oral, small molecule MRGPRX2 antagonist
 - CIndU (SD) Ph 2: n= 30, complete response 30% at 4 wk
 - CSU Ph 2 data is pending
- **Dual mechanism:** can mitigate neurogenic itch as well as IgE-independent MC activation



Take “consult” message

- **Despistaje de comorbilidades en prurigo nodular**
- **Medicina de precisión en urticaria crónica espontánea**
- **Crecimiento exponencial en cuanto a desarrollo de nuevas moléculas**

*A un nuevo nivel de
conocimiento científico*



AAD ANNUAL MEETING **2026**

AEDV

highlights
Denver, Colorado

27 — 31
Marzo

Una iniciativa de:



ACADEMIA ESPAÑOLA
DE DERMATOLOGÍA
Y VENEREOLOGÍA



FUNDACIÓN
PIEL SANA
ACADEMIA ESPAÑOLA
DE DERMATOLOGÍA
Y VENEREOLOGÍA

Con el patrocinio de:



ucb